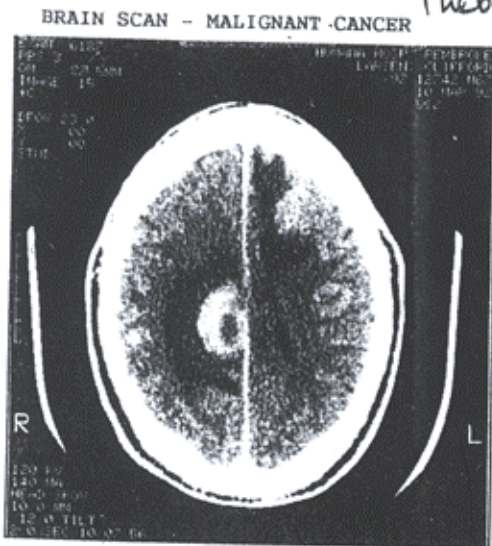


GOODBYE CANCER

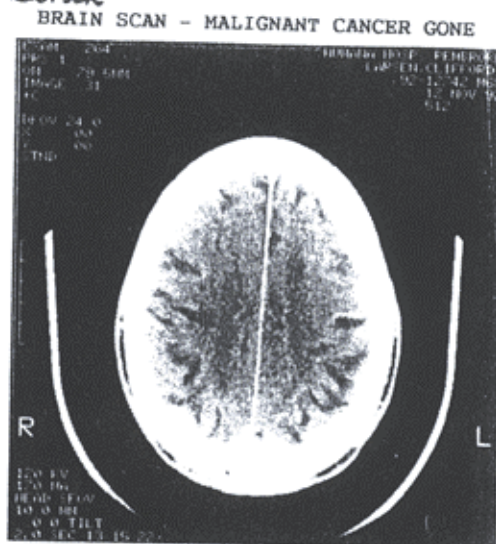
Dear Rodney (Mr Stockton): Jan. 26, 1993

I thank you so much for your cooperation & understanding. We both thank you for giving Clifford back his life. This sounds rather flippant for such an amazing, enormous part of history. God Bless you!

most sincerely,
Phebe Larson



BEFORE:
March 10, 1992
Malignant Melanoma



AFTER:
November 12, 1992
Melanoma disappeared after ingesting the
ALOE #1, Genuine Aloe Vera Gel

NINE YEARS LATER...THE CANCER NEVER RETURNED

The above letter refers to a gentleman, 65 years old, where his cancer, Malignant Melanoma ended up on both sides of his brain and was inoperable, - the Doctors could do no more for him. His life span was (3) weeks. The Doctors reportedly stated there was no way to reduce these tumors in his brain. However, 60 days after consuming the GENUINE ALOE VERA HEALTH DRINK, CAT scans revealed that the tumors on both sides of the brain had reduced dramatically, by better than 50%. Later CAT scans revealed them all but gone. The gentleman is in good health today!

Comments by R.M. Stockton, who has the previous and more recent CAT scans and a copy of the Medical reports supplied by the patient's family.



MEDICAL HISTORY OF CLIFFORD LARSEN
TERMINALLY ILL WITH MELANOMA & LYMPHOMA

Dr. Alfred Ketchum M.D.
Dr. Frederick Moffat, M.D.
Jackson Memorial Hospital
Miami, Florida
May 1980 - December 1990

5/80 Level III Melanoma removal from chest
6/80 Clark's Level IV Melanoma of the left chest wall, wide excision of
Melanoma, left axillary node Lymphadenectomy.
2/82 Basal Cell Carcinoma, Hand and Chest
6/85 Melanoma removed from left flank and left scapular region
3/86 Three Basal Cell Carcinomas excised
5/86 Basal Cell Carcinoma excised
5/86 - 2/92 Multiple Basal Cell Carcinomas removed or frozen by dermatologist
12/90 Metastatic Melanoma Thoracotomy, half of left lung removed by Dr.
Richard Thurer, Humana Hospital, Pembroke Pines, Florida
1/92 Right Adrenal Gland and Gall Bladder removed - Melanoma
3/92 Left tonsil removed - Melanoma
3/10/92 Brain CT scan revealed multiple brain tumors with surrounding Edema.
Masses seen in the left temporal lobe, left occipital lobe and in the parietal
lobes. Also, a small mass in the left frontal lobe. The largest masses are in
the left temporal lobe (measuring about 4 cm) and in the right parietal lobe
(also about 4 cm.) There is a considerable amount of Edema around both
these masses as well as in the two masses over the left convexity.
3/92 Given steroids for Edema and radiation to slow tumor growth
3/92 Doctors give three months to live
3/25/92 Began drinking GENUINE ALOE VERA GEL HEALTH DRINK
5/6/92 Brain CT scan shows decrease in size of lesions and in the degree of
surrounding Edema
8/14/92 Brain CT scan shows significant internal reduction in the overall size of
several of the metastatic lesions
12/12/92 Brain CT scans show the two remaining areas of Metastasis improving
1/28/93 Brain scans show further improving of lesions, no new lesions.
1/93 - 11/95 Clifford continues to get stronger. Now exercises, weighs 200 lbs. No
New Basal Cell Carcinomas or Melanoma have appeared since starting
to drink the GENUINE ALOE VERA GEL HEALTH DRINK in March of
1992. He is now 71 years old.

We have 40 CT Scans, plus complete medical records to show how the CANCER his
body was reversed.

Today Clifford lives a normal life and is in very good health.